

Research Article

Variations of Arterial Supply of the Liver: C.T. Angiographic Study Among Sudanese Adults

Nidal Abubaker Harun^{1*}, Mohamed A/Salam Nurein², Taher Osman Ali³, Tarig Gasim Mohamed Alarabi⁴, Kamal Zaki Ali⁵, Heitham Mutwakil Mohammed⁵, Asim Mohammed Abdalla⁵, Abulqasim M. B. Siddeeg⁵, Ali Gad Karim A. Salih⁵, Samy Ismail Ahmed⁶

¹University of Science and Technology, Collage of Medicine, Department of Anatomy, Omdurman-Sudan

²Albayan College for Science and Technology, Department of Anatomy, Khartoum- Sudan

³National Ribat University, Collage of Medicine, Department of Anatomy, Khartoum - Sudan

⁴Orotta College of Medicine and Health Sciences, Department Medical Sciences, Unit of Anatomy and Embryology, Asmara, Eritrea.

⁵King Khalid University, Collage of Medicine, Department of Anatomy, Abha - Kingdom of Saudi Arabia

⁶Najran University, Collage of Medicine, Department of Anatomy, Najran - Kingdom of Saudi Arabia

ORCID:

Tarig Gasim Mohamed Alarabi: <https://orcid.org/0000-0002-0948-6807>

Abulqasim M. B. Siddeeg: <https://orcid.org/0000-0001-9315-1980>

Ali Gad Karim A. Salih: <https://orcid.org/0000-0002-8471-8241>

Heitham Mutwakil Mohammed: <https://orcid.org/0000-0002-6515-7207>

Samy Ismail Ahmed: <https://orcid.org/0000-0002-9790-6751>

Taher Osman Ali: <https://orcid.org/0000-0001-6751-1460>

Nidal Abubaker Harun: <https://orcid.org/000-0003-0724-2080>

Corresponding Author: Nidal
Abubaker Harun; email:
tarigfuture@gmail.com

Received 22 July 2020

Accepted 30 May 2022

Published 30 September 2022

Production and Hosting by
Knowledge E

© Harun et al. This article is distributed under the terms of the [Creative Commons Attribution License](https://creativecommons.org/licenses/by/4.0/), which permits unrestricted use and redistribution provided that the original author and source are credited.

Editor-in-Chief:

Prof. Nazik Elmalaika Obaid
Seid Ahmed Husain, MD,
M.Sc, MHPE, PhD

Abstract

Hepatobiliary surgery through laparoscopic approach is becoming a routine. Knowledge of extrahepatic arterial tree is essential for surgical and imaging procedures. Anatomical complexity is expected since the liver is developed by merging of lobules with its separate blood supply. This makes a wide range of variations in the pattern of vascular arrangement and so reinforces the need for an accurate understanding of full spectrum of variations. This study aimed to investigate the variations in origin and distribution of extrahepatic arterial supply. Fifty volunteers (32 males and 18 females) aged 20–70 years were randomly recruited from the department of CT scan in Al Amal Hospital, Khartoum North, Sudan. The patients were already candidates for CT angiography with contrast for conditions other than hepatobiliary diseases. The reported data is related to those who accepted to participate in the study. Patients with history of hepatobiliary disease were excluded. 3D views of the scans were treated and the extrahepatic arterial tree was traced in a computer-based software. Key findings suggest that Michel's classification was considered the standard template for description – 76% of them showed Michel's type I classification. Types III and V constituted about 2%. About 4% of the cases were represented by types VI and IX. Other types of variations constituted about 12%. To conclude, although type I classification which describes the textbook pattern of hepatic artery distribution was significantly detected among the Sudanese population, other variants were to be considered since they are related to major arteries like aorta and superior mesenteric.

OPEN ACCESS

Keywords: hepatic artery variations, CT angiography, hepatobiliary, vascular abnormalities

1. Introduction

The study of vascular anatomical variations and its regular updates is essential for the safety practice in the modern surgery, radiology, and transplantation procedures [1]. Many types of vascular variations have been reported for the liver at both dissection laboratories and radiological imaging [2]. The extra blood vessel that supplies the liver lobes is called the accessory hepatic artery (ACh), whereas the vessel risen from an unusual origin is called the replaced hepatic artery (RpH) [3]. It is observed that the usual presentation of the hepatic arterial vasculature was the common hepatic artery which is arising from the celiac axis. The normal hepatic arterial vasculatures are presented in about 50–80% of the population [4]. The variations in the hepatic artery were first described by Michel in 1966 who classified it into 11 types [5, 6] (Table 1). Type I is the common hepatic artery which is one of the three branches of the celiac trunk. Types II, III, and IV are replaced right and left hepatic arteries arising from the superior mesenteric and left gastric arteries. Types V, VI, and VII are accessory right and left hepatic arteries arising from the superior mesenteric and left gastric arteries. Type VIII has replaced right hepatic artery in combination with accessory left hepatic or vice versa. In types IX and X, the whole hepatic artery arises from the superior mesenteric artery (SMA) or left gastric artery (LGA) [2, 3, 5, 7]. Description of a rare variation was reported in which the common hepatic artery gave a branch before the origin of the gastroduodenal artery [7]. The common hepatic artery was seen arising from the SMA according to Ozen [8]. Quadrification of the celiac trunk into splenic, left gastric, common hepatic, and inferior phrenic arteries were reported; moreover, the hepatic proper was divided inside the liver into right and left hepatic branches and to ACh that originated from the SMA [9]. Another pattern of quadrification was reported with celiac trunk divided into splenic, common hepatic, left gastric, and gastroduodenal arteries, also the proper hepatic was seen to continue as a separate right hepatic artery whereas the left branch was arising from the left gastric [10]. This study investigates the presence of new variations in the extrahepatic branches of the hepatic artery using angiographic computerized tomography with contrast among the Sudanese populations.

2. Materials and Methods

This cross-sectional descriptive study was conducted on 50 volunteers (32 male and 18 female) aged 20–70 years between September 2015 and March 2017 at Alamal National Hospital, Khartoum North, Sudan. The hospital is a referral hospital for CT angiography scanning with contrast.

The sample was collected from patients attending the CT department to be scanned using contrast for investigations other than liver angiography. A call for participation was set and all candidates who agreed to participate in the study were included in the sample. Thus, it is considered as a convenient sample. This is because it was not practical and ethical to subject the candidates to CT scanning with contrast for research only.

The announcement for the volunteers to participate in this study was boarded in the department of medical imaging. Any volunteer with a medical history of hepatobiliary disease was excluded. Consent was obtained individually from each candidate after further counselling, as well as the study was approved by the academic committee of the College of Postgraduate Studies, National Ribat University, Khartoum, Sudan. Volunteers were prepared for scanning with Omnipaque (80 ml) – an autoinjecting contrast media (non-ionic iodinated). The scan was performed using contrast and the scanner was Toshiba AquilionTM 64 slice (Toshiba Medical Systems, Nasu, Japan) – version 3.0 software which includes Digital Imaging and Communications in Medicine (DICOM), the 3D views analysis was modulated according to the software options. Exposure to radiation was highly controlled for each volunteer.

3. Results

Out of the 50 volunteers, 48% were 60–70, 30% were 40–59, and 22% were 20–39 years old (Figure 1). In 76% of cases, the hepatic artery was emerging from the celiac trunk (Type I of Michel's classification). The distribution of the variations types III, V, VI, and IX were 2%, 2%, 4%, and 4%, respectively. In 12% of the cases, the variations were class XI (not matching the variations of Michel's classification from I to X) (Table 1). It was including a common hepatic artery arising as a direct branch of aorta and two hepatic arteries each originating separately (Figures 2 & 7). No significant correlation between the variation and the sex was found (P -value = 0.122).

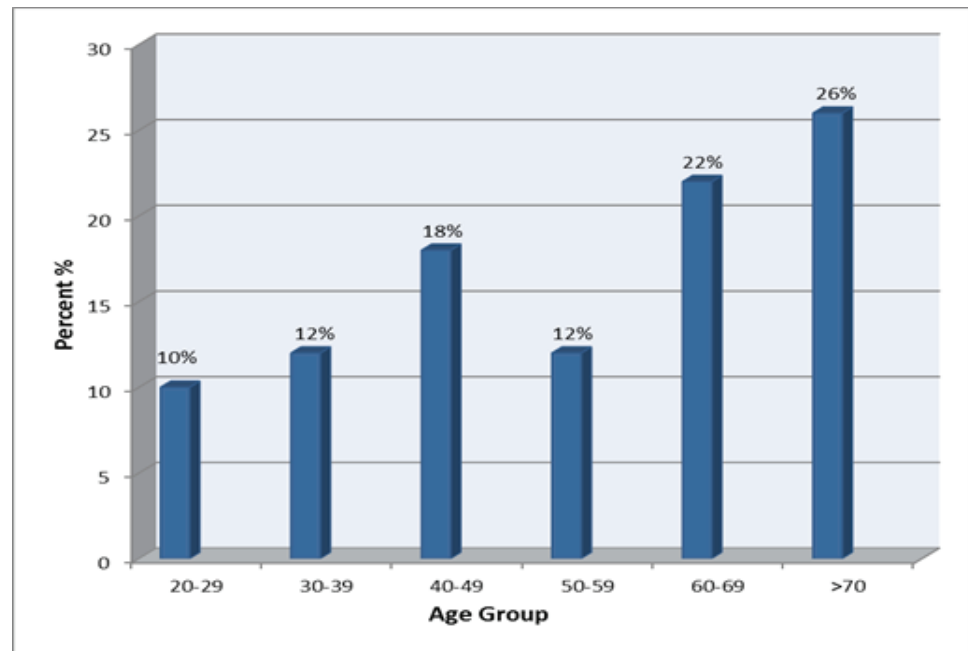


Figure 1: Distribution of the study population by age group.

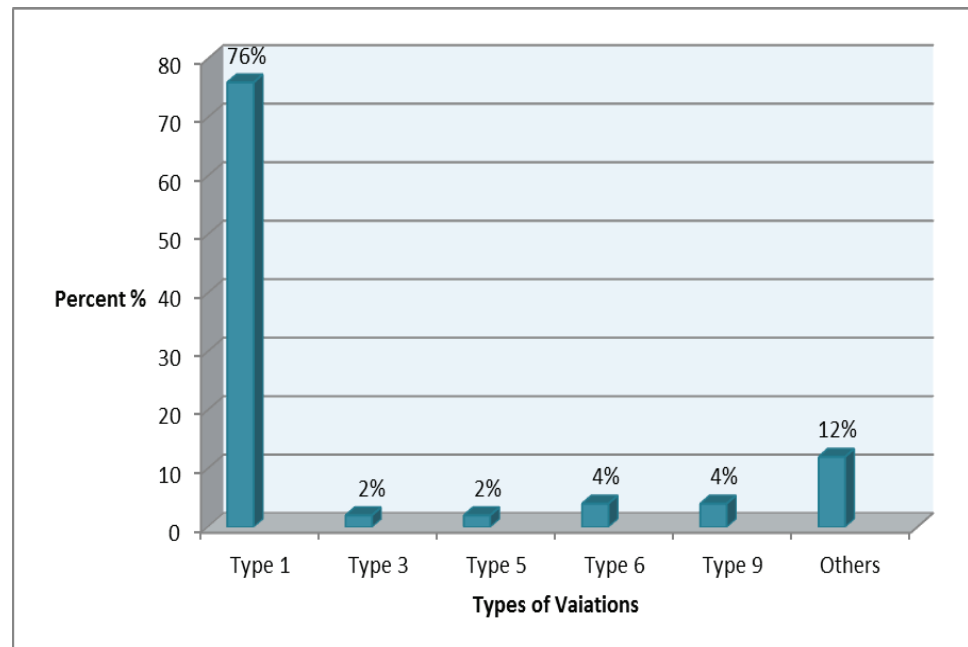


Figure 2: Distribution of study population according to the type of hepatic artery variation.

4. Discussion

Any anatomical changes in the liver vasculature should be reported to improve the practice in the fields of laparoscopic hepatobiliary surgery, interventional radiology, and liver transplantation. This study tried to investigate the presence of variations in the hepatic artery concerning the origin and extrahepatic branching among Sudanese

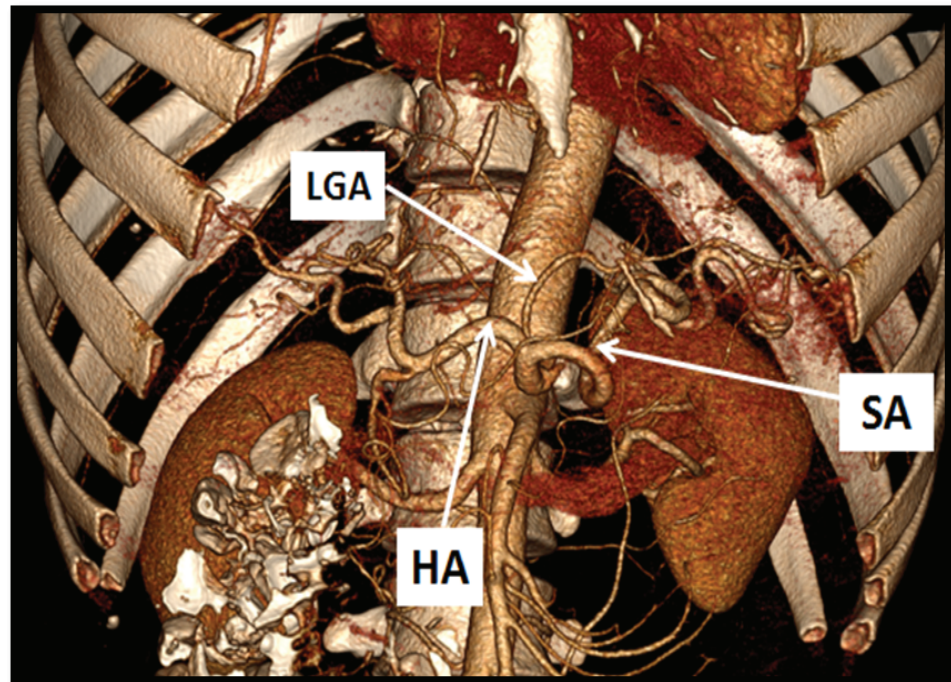


Figure 3: CT angiography of Toshiba **AquilionTM** 64 slice (Toshiba Medical Systems, Nasu, Japan) showing Michel type I, the celiac trunk dividing into three branches – left gastric artery (LGA), common hepatic artery (CHA), and splenic artery (SA).

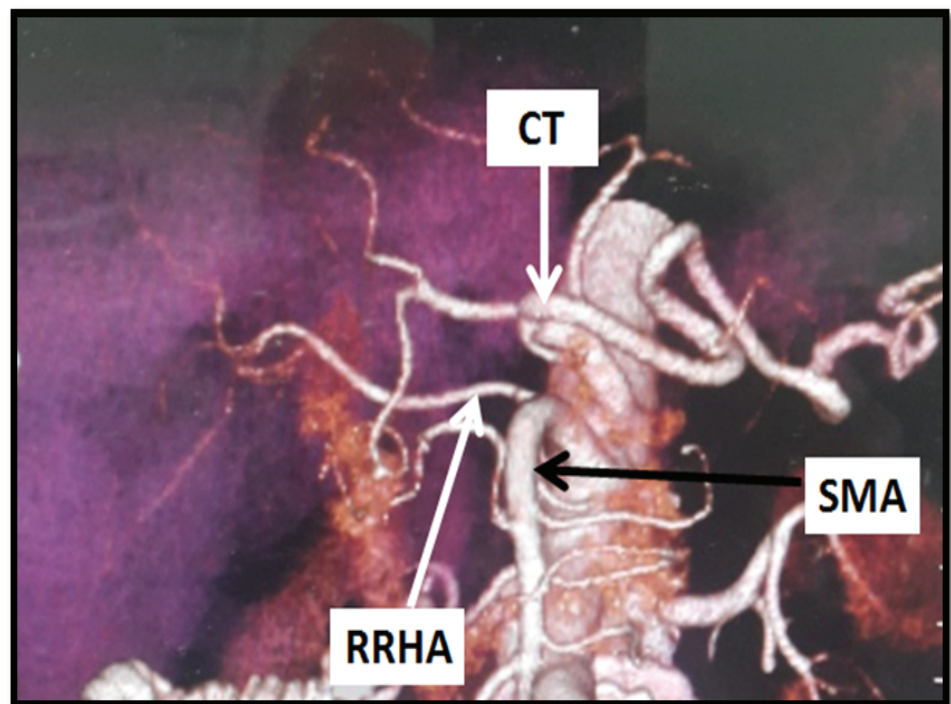


Figure 4: CT angiography of Toshiba **AquilionTM** 64 slice (Toshiba Medical Systems, Nasu, Japan) showing Michel type III replaced right hepatic artery from superior mesenteric artery + quadrification of the celiac trunk.

using CT angiography, which is why this study has classified the variations according

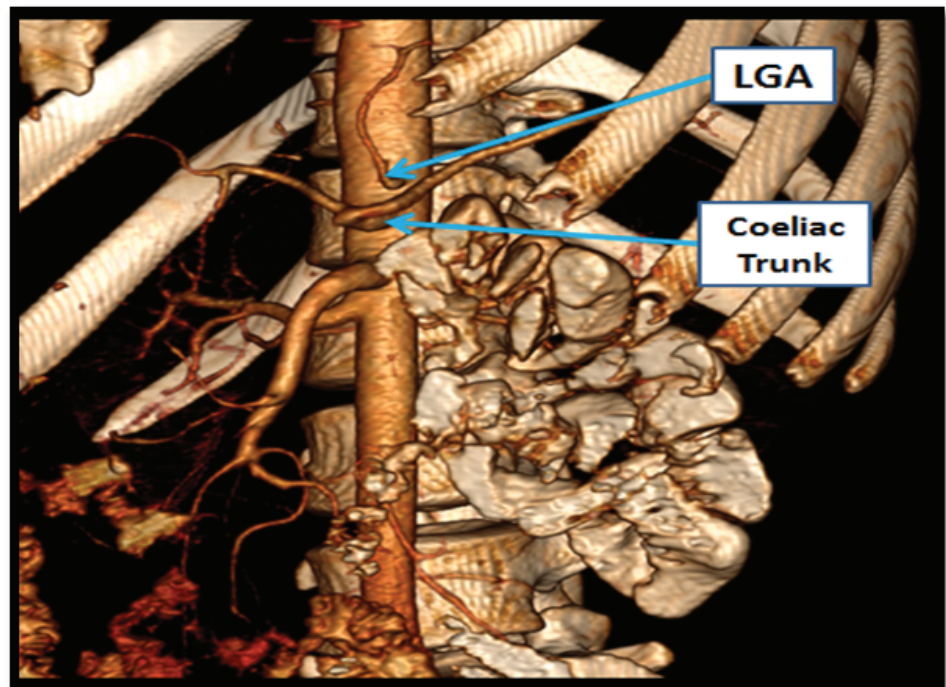


Figure 5: CT angiography of Toshiba **Aquilion**TM 64 slice (Toshiba Medical Systems, Nasu, Japan) showing the LGA arising directly from the aorta.

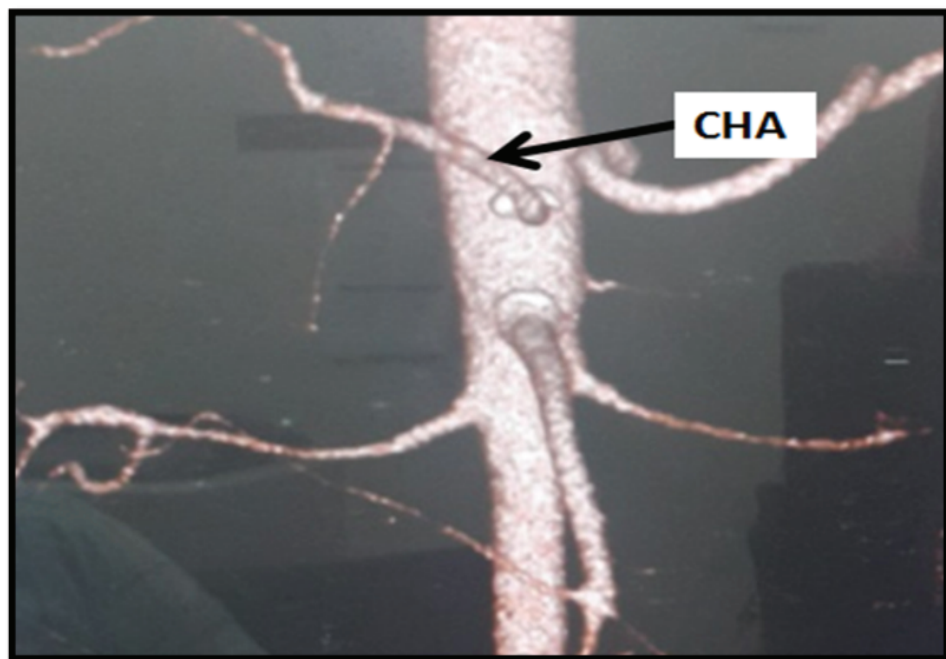


Figure 6: CT angiography of Toshiba **Aquilion**TM 64 slice (Toshiba Medical Systems, Nasu, Japan) showing the common hepatic artery arising from the aorta.

to Michel's categorization [7] which seems to describe the difference between the accessory and replaced hepatic arteries [11, 12]. Other studies such as Suzuki [13] used another method of classification based on the distribution of the hepatic artery at the

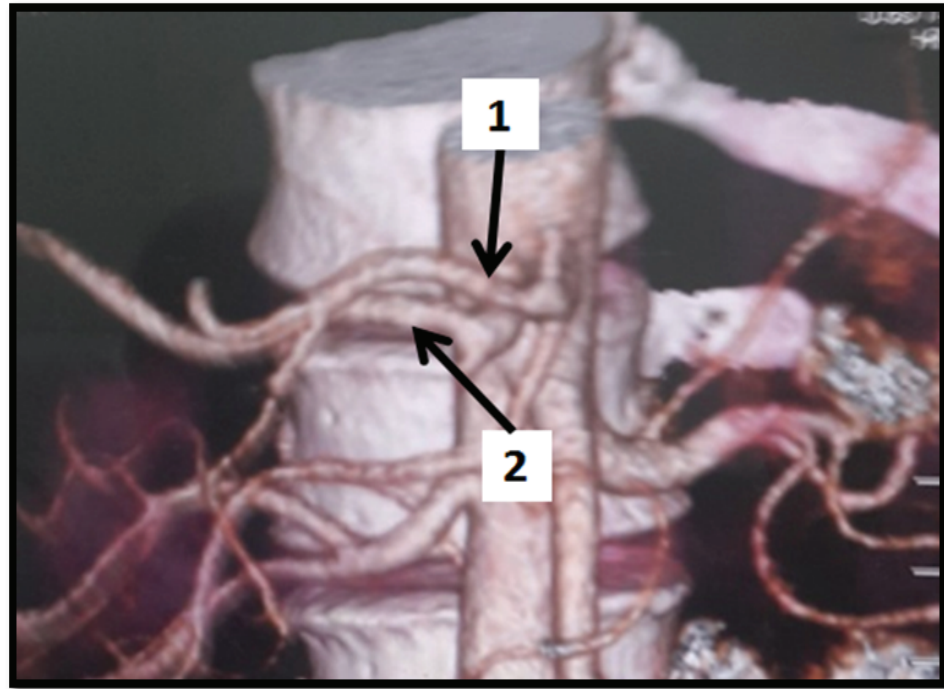


Figure 7: CT angiography of Toshiba **AquilionTM** 64 slice (Toshiba Medical Systems, Nasu, Japan) showing double hepatic arteries – one arising from the celiac trunk (1) and the other originating as a direct branch from the aorta (2).

TABLE 1: Michel's classification of hepatic artery variations.

Type	Description
I	Normal anatomy of hepatic artery
II	Replaced LHA arising from LGA
III	Replaced RHA arising from SMA
IV	Replaced LHA and replaced RHA
V	Accessory LHA arising from LGA
VI	Accessory RHA arising from SMA
VII	Accessory LHA and RHA
VIII	Replaced RHA + accessory LHA/Replaced LHA + accessory RHA
IX	Entire hepatic trunk arising from SMA
X	Entire hepatic trunk arising from LGA
XI	For any variant not described for type I–X

Source: Classification by Michel

(1966) [3, 5, 6].

Porta-hepatis area of the liver. Another method was modified Michel's classification with the reduction of the variation's groups from ten to five in addition to a sixth group for the variants not included [14]. Regarding the normal presentation of the hepatic artery (typically type I; Figure 3), the study results were 76%, which is in line with the study by Kamath [15] with 75% and Ozdemir [16] with 68.6%; but in contrast with the study of Saidi [17] which revealed a 95.1% for the current type. Type III was reported to be the next

common type in many studies [8, 18, 19], which disagrees with our results that describe the percentages of types III and V as the least frequent types of variations with 2% for each (Figure 4). However types VI and IX were reported as 4% each, which agrees with the Gumus study [18]. Besides, 12% of the variations in this study did not match any of the Michel's classifications (Figures 5 & 6).

5. Conclusion

The presence of the textbook picture of the extrahepatic course of the hepatic artery should be investigated in a usual survey. Some of the variations were found to align with Michel's classification whereas others were found to be out of the classification (type XI). Among the limited examined Sudanese volunteers, 24% were of unusual (abnormal) anatomical presentation which is alarming for a community blueprint as well as such results can build a new update for the anatomy and morphology sciences. Therefore, further research and investigations are recommended to detect the actual percentage and distribution of hepatic arterial vasculature variations as well as other anatomical variants.

Acknowledgments

The authors would like to thank the staff of the radiology department in Alamal National Hospital, with special regards to Dr Abdulrahman Mohamed Alnoor for his valuable collaboration.

Ethical Considerations

Consent was obtained from all participants.

Competing Interests

None

Availability of Data and Material

All relevant data and methodological details pertaining to this study are available to any interested researchers upon reasonable request to corresponding author.

Funding

None.

References

- [1] Saritha, S. (2014). Surgical anatomy of coeliac trunk variations an autopsy series of 40 dissections. *Global Journal of Medical research: i Surgeries and Cardiovascular System*, 14(1), 41–46.
- [2] Pulakunta, T., Potu, B. K., Gorantla, V. R., Vollala, V. R., & Thomas, J. (2008). Surgical importance of variant hepatic blood vessels: A case report. *Jornal Vascular Brasileiro*, 7(1), 84–86. <https://doi.org/10.1590/S1677-54492008000100016>
- [3] Jeleu, L., & Angelov, A. (2015). A rare type of hepatobiliary arterial system in man—presence of accessory left and replaced right hepatic arteries and double cystic arteries. *Anatomy*, 9(2), 100–103. <https://doi.org/10.2399/ana.15.010>
- [4] Staśkiewicz, G., Torres, K., Denisow, M., Torres, A., Czekajska-Chehab, E., & Drop, A. (2015). Clinically relevant anatomical parameters of the replaced right hepatic artery (RRHA). *Surgical and Radiologic Anatomy*, 37(10), 1225–1231. <https://doi.org/10.1007/s00276-015-1491-y>
- [5] Chiang, K., Chang, P.-Y., Lee, S. K., Yen, P. S., Ling, C. M., Lee, W. S., Lee, C. C., & Chou, S. B. (2005). Angiographic evaluation of hepatic artery variations in 405 cases. *Chinese Journal of Radiology-Taipei*, 30(2), 75.
- [6] Zagga, A., Usman, J. D., Abubakar, B., & Tadros, A. T. (2010). Accessory right hepatic artery originating from the superior mesenteric artery: Report on three cadaveric cases from Sokoto, North-Western Nigeria and review of literature. *Orient Journal of Medicine*, 22(1–4). <https://doi.org/10.4314/ojm.v22i1-4.63575>
- [7] Saba, L. (2012). CT Imaging of hepatic arteries. In: L. Saba (Ed.) *Computed tomography – Clinical applications*. InTech Open. <https://doi.org/10.5772/24770>
- [8] Özen, K., Büyükmumcu, M., Özbek, O., Kabakçı, A. A., & Şahin, G. Case report: Hepatomesenteric trunk. *İbni Sina Tıp Bilimleri Dergisi*, 1(3), 52–55.
- [9] Nayak, S., Ashwini, L. S., Swamy Ravindra, S., Abhinitha, P., Marpalli, S., Patil, J., & Ashwini Aithal, P. (2012). Surgically important accessory hepatic artery-A case report. *Journal of Morphological Sciences*, 29(3), 187–188.
- [10] Sathidevi, V., & Rahul, U. (2013). Coeliac trunk variations-case report. *International Journal of Scientific and Research Publications*, 3(2), 1–4.

- [11] Sebben, G. A., Rocha, S. L., Sebben, M. A., Filho, P. R. P., & Gonçalves, B. H. H. (2012). Variations of hepatic artery: Anatomical study on cadavers. *Revista do Colégio Brasileiro de Cirurgiões*, 40(3), 221–226.
- [12] López-Andújar, R., Moya, A., Montalvá, E., Berenguer, M., De Juan, M., San Juan, F., Pareja, E., Vila, J. J., Orbis, F., Prieto, M., & Mir, J. (2007). Lessons learned from anatomic variants of the hepatic artery in 1,081 transplanted livers. *Liver Transplantation*, 13(10), 1401–1404. <https://doi.org/10.1002/lt.21254>
- [13] Suzuki, T., Nakayasu, A., Kawabe, K., Takeda, H., & Honjo, I. (1971). Surgical significance of anatomic variations of the hepatic artery. *American Journal of Surgery*, 122(4), 505–512. [https://doi.org/10.1016/0002-9610\(71\)90476-4](https://doi.org/10.1016/0002-9610(71)90476-4)
- [14] Hiatt, J. R., Gabbay, J., & Busuttil, R. W. (1994). Surgical anatomy of the hepatic arteries in 1000 cases. *Annals of Surgery*, 220(1), 50–52. <https://doi.org/10.1097/00000658-199407000-00008>
- [15] Kamath, B. (2015). A study of variant hepatic arterial anatomy and its relevance in current surgical practice. *International Journal of Anatomy and Research*, 3(01), 947–953. <https://doi.org/10.16965/ijar.2015.124>
- [16] Özdemir, F.A.E., Ökten, R. S., Özdemir, M., Eren, M., Küçükay, F., Tola, M., & Şenol, E. (2014). Evaluation of hepatic vascular anatomy by multidetector computed tomography angiography in living liver right lobe donors. *Akademik Gastroenteroloji Dergisi*, 13(1), 01–06.
- [17] Saidi, H., Karanja, T. M., & Ogengo, J. A. (2007). Variant anatomy of the cystic artery in adult Kenyans. *Clinical Anatomy*, 20(8), 943–945. <https://doi.org/10.1002/ca.20550>
- [18] Gümüş, H., Bükte, Y., Özdemir, E., Sentürk, S., Tekbas, G., Önder, H., Ekici, F., & Bilici, A. (2013). Variations of the celiac trunk and hepatic arteries: A study with 64-detector computed tomographic angiography. *European Review for Medical and Pharmacological Sciences*, 17(12), 1636–1641.
- [19] Saylisoy, S., Atasoy, C., Ersöz, S., Karayalçın, K., & Akyar, S. (2005). Multislice CT angiography in the evaluation of hepatic vascular anatomy in potential right lobe donors. *Diagnostic and Interventional Radiology (Ankara, Turkey)*, 11(1), 51–59.