بسم الله الرحمن الرحيم
Omdurman Islamic University Journal of Applied Sciences
(OIUJ)-(ASC)
للعلوم التطبيقية مجلة جامعة أم درمان الاسلامية
https://journal.oiu.edu.sd/index.php/oiuj
https://doi.org/ 10.52981/oiujas.v21i3.3391
2025; 21(3)1-4
ISSN: 5361-1858

Neonatal Haematemesis Due to Multiple Gastric Ulcers: A Case Report

Sulieman Mohammed Tahir Hussien[1], Hala Mohammed Hussein Moussa Azzam[2], Shady Hamed Safwat Zaki[3]

1. Pathology Specialist, Sinaw Hospital, Sinaw, Oman
2. Specialist in Pediatrics, Sinaw Hospital, Sinaw, Oman
3. Specialist in Pediatrics, Sinaw Hospital, Sinaw, Oman

To cite this article:
Sulieman Mohammed Tahir Hussien, Hala Mohamed Hussein Azzam, Shady Hamed Safwat Zak, Neonatal Haematemesis Due to Multiple Gastric Ulcers: A Case Report , Omdurman Islamic University Journal, Sudan

ISSN: 5361-1858

https://doi.org/10.52981/oiujas.v21i3.3391

Abstract

Background: Upper gastrointestinal bleeding in neonates is rare, with swallowed maternal blood being the most frequent cause. Other etiologies, including gastritis, esophagitis, and peptic ulcer disease, should be considered. Maternal medication exposure, such as aspirin, may increase susceptibility to gastric mucosal injury.

Objective: To report a rare case of multiple gastric ulcers in a full-term neonate and highlight the potential association with maternal aspirin uses.

Methods: A descriptive single case report analyzing clinical presentation, laboratory workup, imaging, endoscopy, histopathology, and treatment response.

Case Summary: A full-term male neonate developed massive hematemesis and melena within 48 hours of life. The mother had received low-dose aspirin for two months for preeclampsia prophylaxis. Endoscopy revealed multiple gastric ulcers with friable mucosa; histopathology confirmed mucosal erosion with mild inflammatory changes. The infant was stabilized, transfused, and successfully treated with proton pump inhibitors, with no recurrence on follow-up.

Conclusion: Primary gastric ulceration should be considered in neonatal upper gastrointestinal bleeding, even in otherwise healthy term infants. Maternal aspirin exposure may represent a contributing risk factor. Early endoscopy is essential for diagnosis and management.

Keywords: Neonate, Gastric ulcer, Hematemesis, Melena, Endoscopy, Aspirin

Introduction

Upper gastrointestinal (GI) bleeding in neonates is uncommon but potentially life-threatening. Swallowed maternal blood is the most frequent cause, while other etiologies include gastritis,

esophagitis, and peptic ulcer disease [1, 2]. Neonatal gastric ulcers are usually associated with systemic illness or perinatal stress, including prematurity, sepsis, coagulopathy, hypoxia, hypovolemia, intracranial hemorrhage, metabolic acidosis, hypoglycemia, and milk protein allergy [1].

In older children and adults, NSAID use, Helicobacter pylori infection, and Zollinger–Ellison syndrome are recognized causes [3]. Maternal medication exposure—particularly aspirin—has been hypothesized as a potential risk factor for neonatal gastrointestinal complications [4, 5]. We present a case of a healthy full-term neonate who developed severe hematemesis and melena due to multiple gastric ulcers, with maternal low-dose aspirin use during pregnancy as the only identifiable risk factor.

Case Presentation

A male neonate weighing 3.2 kg was delivered at 42 weeks' gestation via induced vaginal delivery to a 24-year-old gravida 3 para 2 mother. Pregnancy and delivery were uneventful, except for maternal low-dose aspirin use for two months as preeclampsia prophylaxis. APGAR scores were 8 and 9 at one and five minutes, respectively. Vitamin K was administered at birth, and breastfeeding was established.

At 26 hours of life, the infant developed sudden, profuse hematemesis. On admission, he was hemodynamically stable (HR 140 bpm, RR 40/min, BP 65/44 mmHg, SpO_2 98% on room air, T 37°C). He was alert, mildly icteric, feeding well, and without respiratory distress, abdominal tenderness, hepatosplenomegaly, or neurological abnormalities.

Laboratory findings:

- WBC: 13.87 $\times 10^3/\mu L$ (80% neutrophils)
- Hb: 13 g/dL; Hct: 35.6%
- Platelets: 287 $\times 10^3/\mu L$
- Blood group: O-ve
- Direct antiglobulin test (polyvalent): negative
- Glucose in serum: 5.18 mmol/l
- Coagulation profile: PT: 16.1 seconds, APTT: 31.2 seconds, INR: 1.46
- Liver function test: Total bilirubin: 115 µmol/L (conjugated: 8.98 µmol/L), AST: 54.2 iU/L, ALT: 16.28 iU/L, Protein (total): 60.82 g/l. Albumin: 41.38 g/l, ALP: 164.22 u/l
- Electrolytes/renal profile: within normal limits
- Blood culture: negative

Five hours later, he passed melena, became pale and lethargic, with Hb 6.9 g/dL and platelets 146 $\times 10^3/\mu L$. He was resuscitated with IV fluids, received packed red blood cells, and transferred to a tertiary center.

Endoscopy findings:

Esophagus and duodenum: normal

Stomach: multiple small ulcers with clean bases and friable mucosa, no active hemorrhage

Histopathology: Gastric biopsies showed surface erosion, mild lymphoplasmacytic

infiltration, and glandular atrophy, without microorganisms or viral cytopathic changes.

Management and outcome: The infant received IV proton pump inhibitors, transitioned to oral therapy for one month, and IV ampicillin plus gentamicin for five days. Clinical recovery was rapid, with no further bleeding. Growth and development were normal at one- and two-month follow-up.

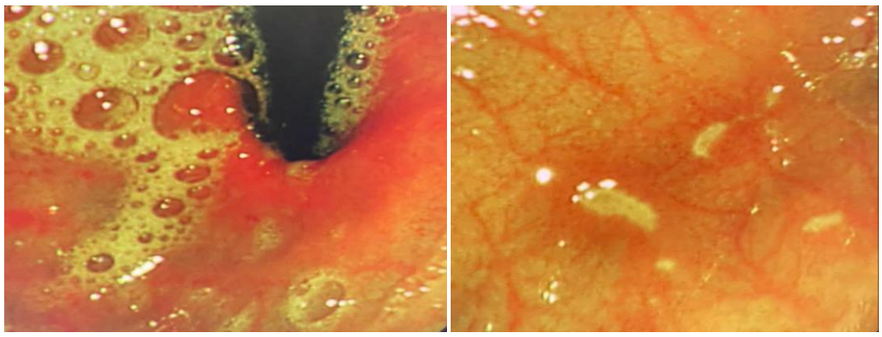

Figure 1: EGD showing multiple gastric ulcers

EGD: esophagogastroduodenoscopy

Discussion

Gastric acid secretion is present at birth in both preterm and term neonates [6], predisposing the gastric mucosa to injury under stress. Neonatal gastric ulceration is rare and usually linked to systemic illness or perinatal complications [1, 2].

In our case, the absence of prematurity, sepsis, hypoxia, or coagulopathy suggests a different mechanism. Maternal aspirin use emerges as the most plausible contributor. Aspirin irreversibly inhibits prostaglandin synthesis, reducing gastric mucosal defense. Although low-dose aspirin is widely prescribed for preeclampsia prophylaxis and considered generally safe, recent studies suggest rare neonatal bleeding risks, including intrapartum, postpartum, and potentially gastrointestinal complications [4, 5].

Comparable reports exist. Bell et al. [7] described perforated stress ulcers in critically ill infants, while Joshi et al. [2] linked ulcers with sepsis. Tijerina et al. [8] and Alan et al. [9] reported healthy neonates presenting with severe hemorrhagic gastritis or ulcers without clear risk factors. Lazzaroni et al. [1] emphasized that upper GI bleeding can occur in term neonates without identifiable triggers.

In summary, this case highlights the importance of considering primary gastric ulceration as a cause of upper gastrointestinal bleeding in otherwise healthy neonates. Maternal low-dose aspirin exposure may represent a contributing risk factor, although causality cannot be confirmed. Early endoscopic evaluation proved essential for diagnosis and guided appropriate management with proton pump inhibitors, leading to full recovery. While this case adds to the limited literature on neonatal gastric ulcers, further research is required to substantiate the association with maternal aspirin use and to inform clinical practice.

Limitations and Future Directions

This report has several limitations. As a single-case study with short follow-up, its findings cannot be generalized, and the observed association between maternal aspirin use and neonatal gastric ulceration remains speculative.

Other potential etiologies, such as Helicobacter pylori infection, viral causes, or unrecognized perinatal stressors, were not fully excluded. Additionally, a detailed maternal gastrointestinal

evaluation and comprehensive drug history beyond aspirin were not obtained, which may have overlooked other risk factors.

Future studies are needed to better define the relationship between maternal aspirin exposure and neonatal gastric ulceration. Larger case series and prospective studies could help clarify causality, identify additional risk factors, and determine the true incidence of this condition. Long-term follow-up research is also warranted to evaluate recurrence and outcomes in affected neonates.

Conclusion

Neonatal gastric ulceration, though rare, should be considered in cases of upper GI bleeding in otherwise healthy infants. Maternal aspirin exposure may represent a potential risk factor. Prompt endoscopic evaluation is essential for accurate diagnosis and management. Proton pump inhibitor therapy is effective, and outcomes are favorable with timely intervention.

References

1. Lazzaroni M, Petrillo M, Tornaghi R, et al. Upper GI bleeding in healthy full-term infants: a case-control study. Am J Gastroenterol. 2002; 97(1):89–94. doi:10.1111/j.1572-0241.2002.05443.x
2. Joshi A, Shrestha PS, Dangol S, et al. Stress-induced gastric ulcers presenting as massive rectal bleeding in a newborn. Kathmandu Univ Med J. 2016;14(54):186–189. PMID: 28166080
3. Owensby S, Taylor K, Wilkins T. Diagnosis and management of upper gastrointestinal bleeding in children. J Am Board Fam Med. 2015;28(1):134–145. doi:10.3122/jabfm.2015.01.140153
4. Hastie R, Tong S, Wikström A-K, et al. Aspirin use during pregnancy and the risk of bleeding complications: a Swedish population-based cohort study. Am J Obstet Gynecol. 2021; 224:95.e1–95.e12. doi:10.1016/j.ajog.2020.07.023
5. Zhang F, Wang H, et al. Effect of low-dose aspirin intervention on pre-eclampsia prevention in high-risk pregnant women and its impact on postpartum hemorrhage. Front Med (Lausanne). 2024. Available from: https://www.frontiersin.org/journals/medicine/articles/10.3389/fmed.2024.1414697/full
6. Hyman PE, Clarke DD, Everett SL, et al. Gastric acid secretory function in preterm infants. J Pediatr. 1985; 106(3):467–471. doi:10.1016/S0022-3476(85)80682-X
7. Bell MJ, Keating JP, Ternberg JL, et al. Perforated stress ulcers in infants. J Pediatr Surg. 1981; 16(6):998–1002. doi:10.1016/S0022-3468(81)80864-0
8. Tijerina Tijerina G, Oldak Skvirsky D, Cázares Méndez JM, et al. gastrointestinal bleeding in a full-term infant: a case report. Arch Clin Case Stud. 2020; 2(4):ACCS.MS.ID.000543. doi:10.33552/ACCS.2020.02.000543
9. Alan S, Vural SN, Gulerman HF, et al. Life-threatening massive upper gastrointestinal bleeding in a term and healthy baby. Proc (Bayl Univ Med Cent). 2023;36(2):253–255. doi:10.1080/08998280.2022.2140545